

CASE REPORT

Open Access

## Xanthogranulomatous Inflammation of Salivary Gland Diagnosed By Fine Needle Aspiration Cytology- A Rare Case Report

Khairwa Anju<sup>1,2</sup>

<sup>1</sup>Specialist pathology Department of Pathology, ESIC Model hospital, Gurugram

<sup>2</sup>Assistant professor, Department of Pathology, University College of Medical Sciences, Delhi, India

### ABSTRACT

Xanthogranulomatous (XG) inflammation is a chronic inflammatory condition characterized by an inflammatory response of foamy macrophages. XG inflammation occurs in many organs like kidney, gallbladder, colon, prostate, retroperitoneum and ovary. Here, presented a rare case of Xanthogranulomatous inflammation of salivary gland (XGS) diagnosed by Fine needle aspiration cytology (FNAC). A 60year old male with a history of right submandibular swelling for 20 days along with pain and mild fever grade since last 25 days back. The patient was operated and histologically confirmed Xanthogranulomatous sialadenitis. Thus, FNAC is an inexpensive, rapid, safe, accurate and minimum invasive procedure for the diagnosis of XGS and avoid unnecessary surgical procedures for rule out a malignant tumour.

### ARTICLE HISTORY

Received July 26, 2021

Accepted July 30, 2021

Published July 31, 2021

### KEYWORDS

Myocarditis, Covid-19, BNT162-2, Pfizer

**Keywords:** Xanthogranulomatous, Inflammation, FNAC, Sialadenitis

### Background

Xanthogranulomatous inflammation (XGI) is a chronic inflammatory condition characterized by an inflammatory response of foamy macrophages. It commonly seen in kidney, causative agents exact not known, XGI believed to develop in the setting of a suppurative infection with renal outflow obstruction [1]. Mostly studies demonstrated XG inflammation in parotid gland with slow-growing mass [2-3].

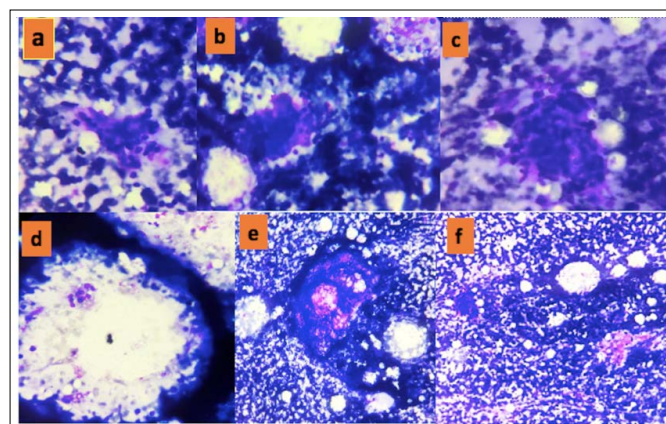
Xanthogranulomatous inflammation also occurs in many organs like colon, prostate, retroperitoneum and ovary. [1,4].

The index study presents a rare case of Xanthogranulomatous inflammation of salivary gland (XGS) diagnosed by Fine needle aspiration cytology (FNAC).

### Case Report

A 60year- old man with a history of right submandibular swelling for 20 days along with pain and mild fever grade since last 25 days back. Physical examination swelling measuring 2x1.5 cm, firm, nontender, mobile and appeared origin from submandibular gland. FNA (fine needle aspiration) was performed in the FNA chamber in pathology department from this swelling with a 21-gauge needle, a 10-cm syringe and pistol handle. Both air-dried and alcohol-fixed smears made for Giemsa and haematoxylin and eosin (H&E) stains. On cytological examination smears were cellular and revealed few small clusters of ductal cells and acinar cells along with infiltration by chronic inflammatory cells (foamy-histiocytes, lymphocytes, plasma cells) and few fibroblasts (figure1a,b,c). In a

background of fragments of fibro-adipocytes, foamy-histiocytes, lymphocytes, histiocytes, fibroblasts, fat globules and stromal particles (figure1 d, e, f). The patient was treated with antibiotics, but he did not respond. The cytologically diagnosed as a chronic inflammatory lesion/ Xanthogranulomatous inflammation (Milan system category II- Nonneoplastic lesion).

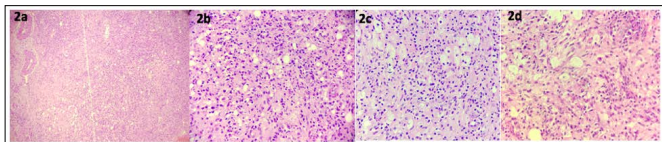


**Figure 1:** (a,b,c) Showed a few small clusters of ductal cells and acinar cells along with infiltration by chronic inflammatory cells (Giemsa x400). (d,e,f)- FNAC revealed stromal fragments, fibroblastic & -adipocytes, foam macrophages, lymphocyte and, fat globules (Giemsa x100).

Further, the patient operated for salivary gland mass, and resected specimen sent for histopathological examination. Grossly, the resected specimen present in multiple fragments, altogether measured 2x2x1cm. On microscopic examination showed multiple small tissue fragments in H&E stain sections. Histology section

**Contact** Anju Khairwa ✉ anjukhairwa@gmail.com 📍 Department of Pathology, University College of Medical Sciences, Delhi, India.

showed foamy macrophages admixed chronic inflammatory cells lymphocytes, plasma cells, histiocytes, eosinophils with focal collagen fibres, fat globules, capillary and fibroblast proliferation seen at periphery (figure 2a,b,c,d). Histology confirmed the diagnosis of chronic inflammatory granulation tissue, suggestive of Xanthogranulomatous inflammation of the salivary gland. The patient did not have radiological investigation.



**Figure 2:** (a) - Depicting fat globules, foamy histiocytes, capillary proliferation (H&E x100), 2 (b,c,d) -Showing chronic inflammatory cells(lymphocytes, foamy histiocytes, plasma cells,macrophages, eosinophis) infiltration with focal halinization and fibroblastic proliferation (H&E x400)

### Discussion

Malek et al. reported a series of 26 patients with Xanthogranulomatous pyelonephritis [5]. Xanthogranulomatous inflammation of kidney has well documented a complication of suppurative renal infection. Xanthogranulomatous inflammation can occur diffuse form or localised mass form which obliterates renal parenchyma [1]. Stephen et al. reported Xanthogranulomatous inflammation described as a complication of needle aspiration [6]. But in our case first-time FNAC did and found Xanthogranulomatous inflammation on cytology. Some studies described XG inflammation associated with Warthin's tumour [2-3, 6]. In our case aetiology not clear for XG inflammation. Few studies reported XG inflammation appeared as mimics of benign tumour-like lesion composed of histiocytes, lipid-laden macrophages, giant cells, fibrosis and mixed chronic inflammatory cells [7]. The author further emphasizes the ability of XGI of salivary gland to mimic a malignant tumour. Bu et al described four cases of XGS, out of them only two cases associated with Warthin 's tumor and in two cases the etiology not clear [8]. That finding corroborated with our study.

Kang et al. reported XG inflammation in submandibular gland a severe inflammatory lesion that included foamy macrophages admixed with neutrophils, eosinophils, lymphocytes, plasma cells, and scattered giant cells [9].

The location, cytology and histomorphology of this study corroborated with our case findings. None of the studies described cutaneous involvement that supported with our research [2-3, 6, 9].

Differential diagnosis of Xanthogranulomatous sialadenitis e.g. inflammatory myofibroblastic tumor, IgG4-related disease and sarcoidosis, neoplastic and paraneoplastic xanthogranulomatosis [10].

So we concluded that FNAC is an inexpensive, reliable, rapid, safe, accurate and minimum invasive procedure for the diagnosis of XG sialadenitis and it can avoid unnecessary surgical procedures for rule out a malignant tumour.

**Grant support:** Nil

**Presentation at a meeting:** Not applicable

**Conflicting Interest:** Nil

**Financial disclosures:** Nil

### References

- [1] Cocco AE, MacLennan GT, Lavertu P, Wasman JK. Xanthogranulomatous Sialadenitis: A Case Report and Literature Review. *Ear, Nose & Throat Journal* 2005; 84:369–374.
- [2] Zainal A, Razif MY, Makhshen M, Swaminathan M, Mazita A. Necrobiotic xanthogranuloma of the parotid gland. *J Laryngol Otol* 2010; 124:569-571.
- [3] Türkmen I, Bas süllü N, Aslan I, Çomunog'lu C, Dog'usoy GB. Xanthogranulomatous sialadenitis clinically mimicking a malignancy: case report and review of the literature. *Oral Maxillofac Surg* 2012; 16:389-392.
- [4] Ladefoged C, Lorent zen M. Xanthogranulomat us inflammation of the female genital tract. *Hisop athology* 1988; 13:541-551.
- [5] Malek RS, Elder JS. Xanthogranulomatous pyelonephritis. *J Urol* 1978: 119: 589-93.
- [6] Stephen MR, Matalka I, Stewart CJ, Macenzie K. Xanthogranulomatous sialadenitis following a diagnosis of Warthin in 's tumour: A possible complication fine-needle aspiration (FNA). *Cytopathology* 1999; 10:276-279.
- [7] Padfield CJH, Choyce MQ, Eveson JW. Xanthogranulomatous sialadenitis. *Histopathology* 1993; 23:488-491.
- [8] Bu L, Zhu H, Racila E, Khaja S, Hamlar D, et al. Xanthogranulomatous Sialadenitis, an Uncommon Reactive Change is Often Associated with Warthin's Tumor. *Head and Neck Pathology* 2020; 14:525–532.
- [9] Kang M, Chung NRKD, Kim JYSDY. Primary Necrobiotic Xanthogranulomatous Sialadenitis with Submandibular Gland Localization without Skin Involvement. *Journal of Pathology and Translational Medicine* 2019; 53:261-265
- [10] Agaimy A, Ihrler S. Xanthogranulomatöses Reaktionsmuster in Speicheldrüsen. *Histomorphologisches Spektrum und Differenzialdiagnose*. *Pathologie* 2014; 35:160-165.